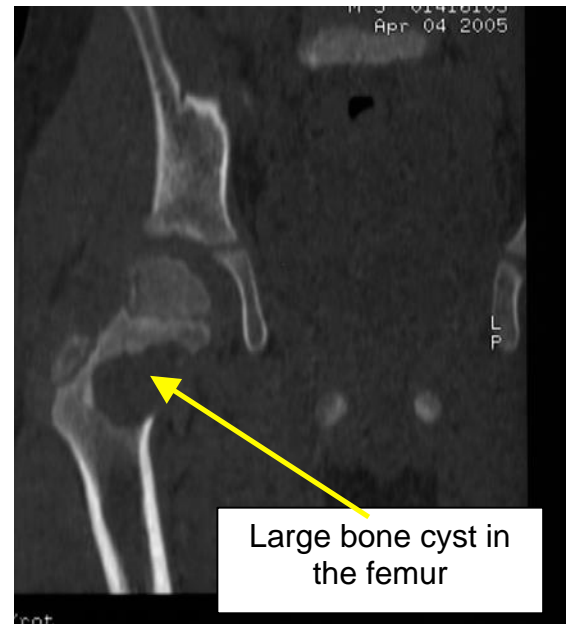
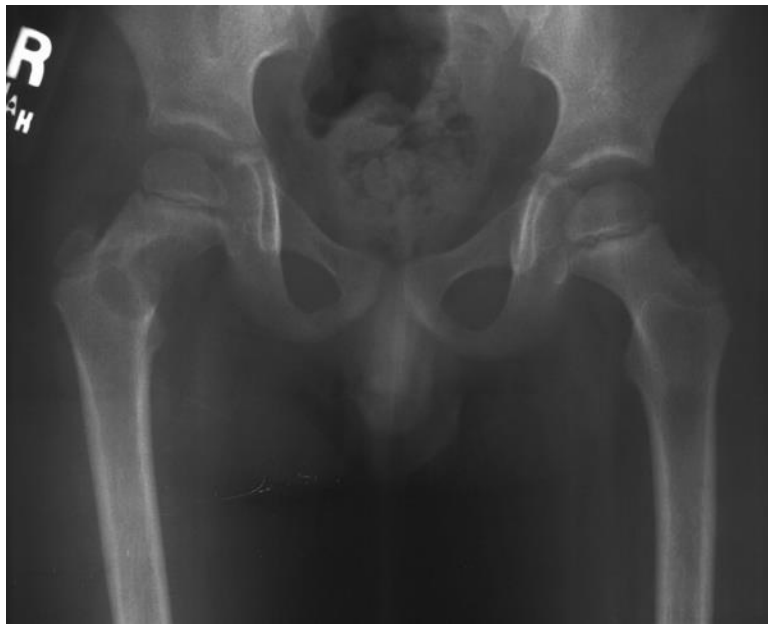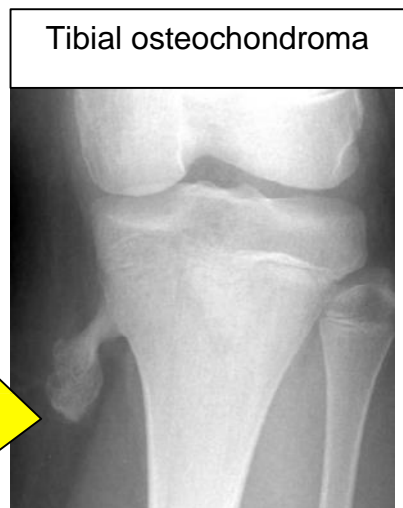


# MUSCULOSKELETAL TUMOR RECONSTRUCTIVE SURGERY

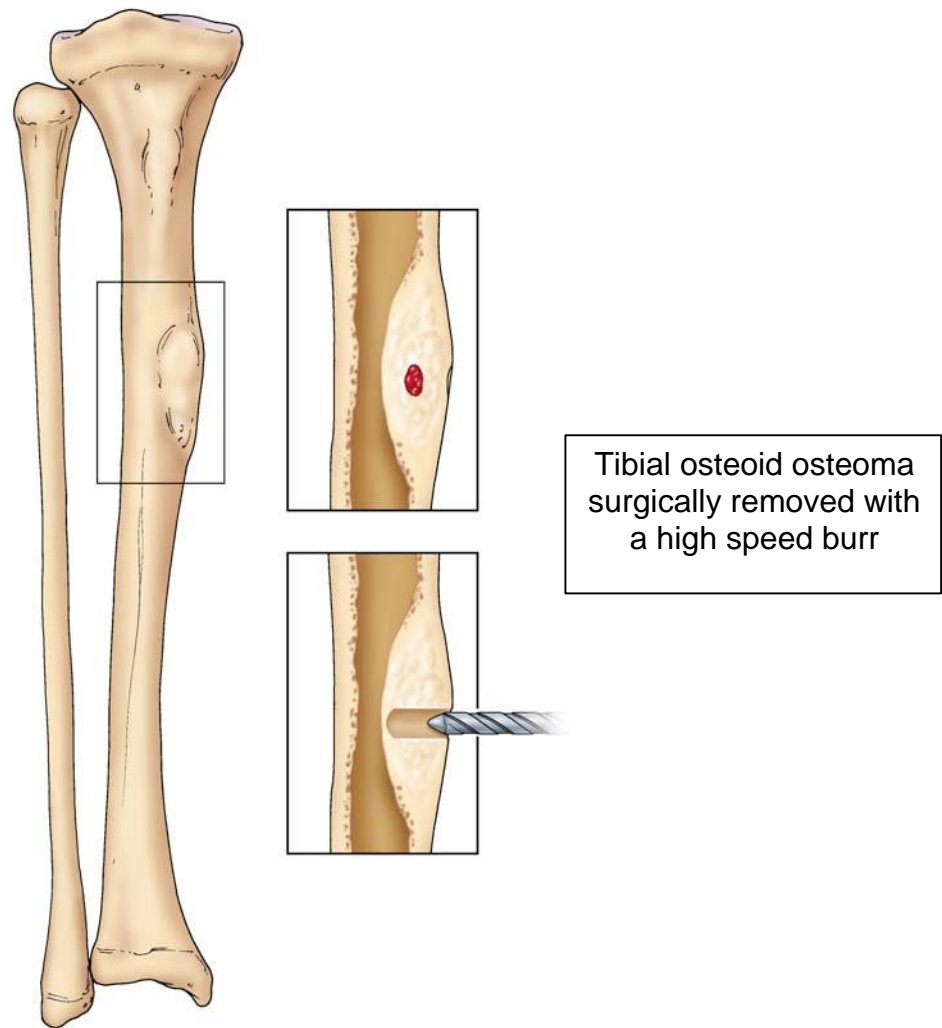
If an abnormality of the bone is detected on physical examination or by x-rays, the first important decision that will be made by the pediatric orthopedic surgeon is whether or not the lesion can be observed or does it require biopsy. Newer imaging modalities such as MRI, CT, and bone scans may allow for the diagnosis of some benign bone tumors without the need or risk of surgery. Many times, however, a biopsy is performed in order to provide an accurate diagnosis and to make recommendations regarding prognosis. If significant bone loss has occurred and an accurate diagnosis can be made pre-operatively or intra-operatively, then reconstructive surgery may also be considered.



In certain circumstances the tumor will not have significantly weakened the bone. For example, an osteochondroma grows on the outside of the bone and can be safely removed from the bone. Most children are able to resume their normal activities in four to six weeks after removal of the tumor/abnormal bone growth.

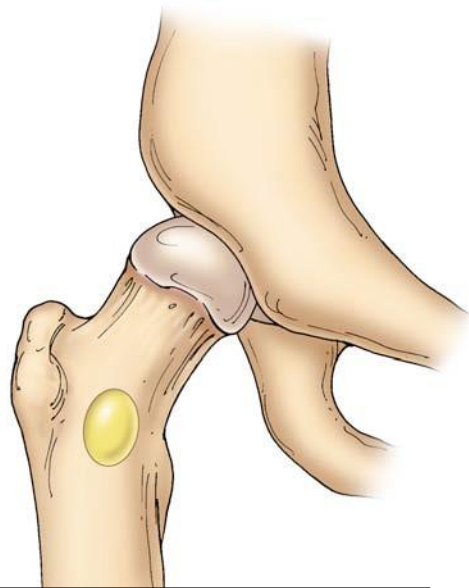


Another type of benign bone tumor, called an osteoid osteoma, can cause abnormal, painful thickening of the bone. If surgery is indicated, the tumor can be removed with a drill, high speed burr, or radio frequency ablation. The treated area of bone may require several months of rest before contact sports are allowed.

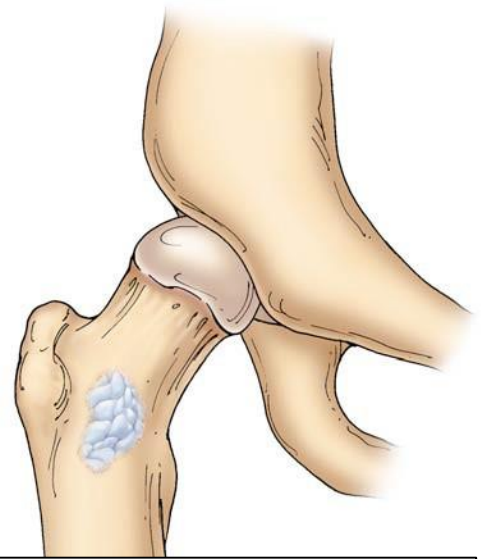


Some benign bone tumors produce a hole in the bone and fill the hole with a liquid or gristle like material. This process may actually thin the bone to the point where it fractures. A fracture in the shin or thigh bone, may result in a significant angular abnormality or growth disturbance.

After an accurate diagnosis is made in the operating room, the pediatric orthopedic surgeon then begins to remove as much of the tumor as is safely possible. Through a combination of scraping the bone and flushing out the abnormal cells, the number of tumor cells is reduced to such a small number that recurrences may be extremely low.

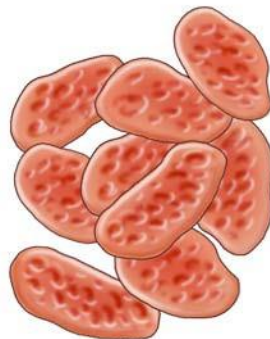


Fluid filled cyst in the bone



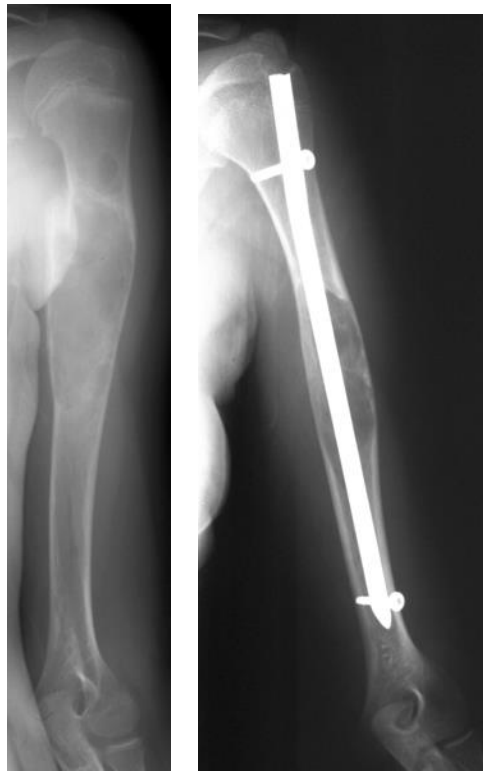Gristle-like material causing a hole in the bone

After removal of the benign tumor, the next step is to fill the hole with bone graft material. Autograft is bone graft that is taken from the patient's own pelvis or other expendable bone. The pelvic bone graft is an excellent source of marrow and new bone cells that can very quickly fill a large defect. Allograft is an inert tissue that has been harvested from donated bone. The tissue banks harvest the bone and then process and test it repeatedly to ensure that there is no living tissue or infection present. The allograft material, since it lacks any bone stimulating cells in it, can only provide a framework upon which the patient's own body will supply the bone creating cells that will then make this dead piece of bone become a living tissue.



Bone graft from the patient is called autograft. Bone graft from a tissue bank is called allograft and does not have any living cells

The large bone cyst was treated with bone graft and placement of an intramedullary rod



In certain circumstances a plate, rods, or screws may be added to provide additional strength to the bone while it is attempting to heal over the next four to six months. The plate or intramedullary rods are specifically designed to help hold the bone in proper alignment while it heals. Whether or not the bone graft material came from the patient or from a tissue bank, the body requires almost six months to make the bone as strong as it was before the tumor was present. In certain individuals the plate may later be removed because of local tenderness, swelling or tendonitis with movement. After the hardware removal, most children are able to resume normal activities in four to six weeks.



Orthopaedics for Kids

©John T. Killian, M.D. & Sharon Mayberry, M.D.